

Prevalence and
risk factors of
osteosarcoma in
dogs

PAGE 2

Pathologic
fractures
associated with
osteosarcoma

PAGE 5

Digital
Squamous Cell
Carcinomas &
the Melanoma
Vaccine

PAGE 8

Treatment and
outcomes, limb
sparing and
amputation

PAGE 11

FOUR LEG NEWS



Update on Osteosarcoma & Digit Cancers

This newsletter is dedicated to all of my past patients that have suffered from either osteosarcoma or digital cancers. As a physiotherapist, I have had my fair share of 'raising the red flag' about patients and abnormal bone pain or digit pain. All practitioners should have neoplasia on their radar as a potential differential diagnosis.

I am pleased to present to Four Leg Members a compilation of recent articles and research papers 'all in one place' to bring you up to date on your knowledge of osteosarcoma and digital cancers. May we all be better practitioners for bolstering our knowledge base.

To the betterment of our profession!

Laurie Edge-Hughes, BScPT, MAnimSt (Animal Physiotherapy), CAFCI, CCRT

Prevalence and risk factors of osteosarcoma in dogs

Rosenberger, J.A., Pablo, N.V., Crawford, C.P., *Prevalence of an intrinsic risk factors for appendicular osteosarcoma in dogs: 179 cases (1996-2005) Journal of American Veterinary Medical Association, 231(7), pp. 1076-1080, 2007.*

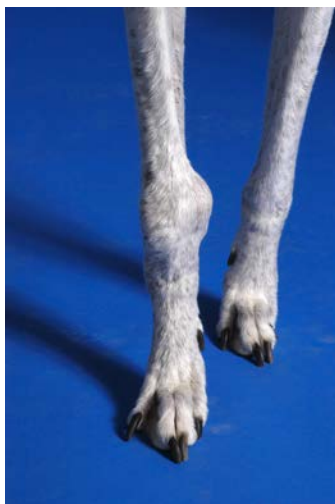


Objective

This study focuses on the inclusion of the greyhound breed in studies of prevalence of osteosarcoma (OSA). Prior to the 1990s the sample size of Greyhounds available in the general pet population was significantly lower than it is now, following the introduction of the practicing of retiring greyhounds from the track into pet homes. Since Greyhounds were previously excluded from the studies by merit of small sample size this study looks at risk factors that may be specific to the breed in comparison to the other breeds commonly associated with OSA, and potentially specific to training for racing.

Methods

This retrospective study was an analysis of a selection of 179 dogs diagnosed with OSA. Factors such as breed, age, sex, and weight were analyzed for significance.



Results

Breed prevalence in this population was calculated by taking the total number of dogs of a known represented breed and dividing that number by dogs of that breed examined at the clinic during the study period. The three breeds with the highest occurrence were the Greyhound (6.2%), the Rottweiler (5.3%), and the Great Dane (4.4%). Within the breeds, body weight was not a significant factor, and neither was sex. However, Greyhounds were significantly older at the time of diagnosis than both the Rottweilers

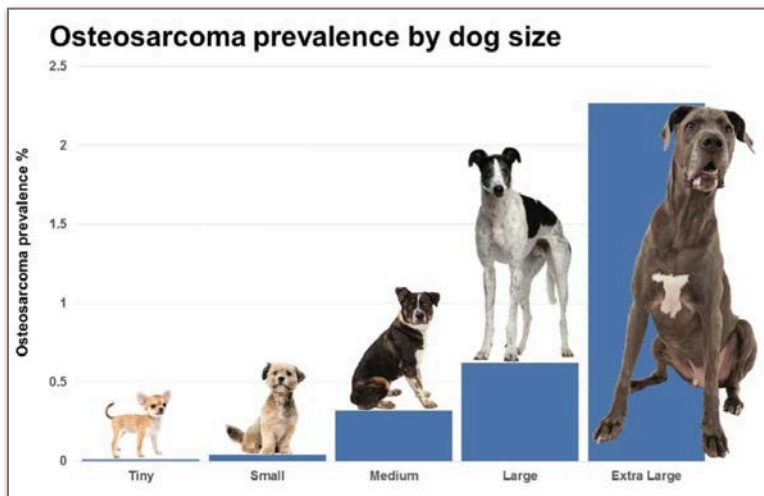
and the Great Danes.

The Great Danes and Rottweilers showed a significantly higher likelihood of OSA on the forelimbs, while there was no significant difference between occurrence in the forelimb or hindlimb of the Greyhounds.

Consistent with previous studies the common sites for tumours among all three breeds were the proximal end of the humerus and the distal end of the radius. However, in the greyhound the proximal end of the femur was also a common OSA site, whereas it has been considered a rare location in previous studies that did not include Greyhounds as a significantly prone breed.

It was not possible for this study to determine whether training for racing was a significant factor in the occurrence of OSA in greyhounds before all the greyhounds included in this study were trained to race competitively.

Amsellem, P.M., Selmic, L.E., Wypij, J.M., Bacon, N.J., Culp, W.T.N., Ehrhart, N.P., Powers, B.E., Stryhn, H., Farese, J.P., *Appendicular osteosarcoma in small-breed dogs: 51 cases (1986-2011)* Journal of American Veterinary Medical Association, 245(2), pp. 203-210, 2014.



Objective

While osteosarcoma is the most common bone cancer in dogs, it is also more common in dogs over 20kg (44 lbs) and many papers concentrate on these larger breeds and mixes in their data. It has, however, been noted that the common tumour location is different in small breed dogs as compared to

large breeds, but study groups of small breed dogs have been too small to draw any specific

conclusions. This paper specifically isolates a study group of smaller body size to investigate pathogenesis and treatment outcomes in small breeds with Osteosarcoma.

Methods

This is a retrospective study of 51 cases of dogs weighing 15kg (33lbs) or less that were diagnosed with a primary appendicular bone tumour. Data from each case collected for meta-analysis included sex, breed, age at diagnosis, tumour location, treatment, and the results of treatment (median survival time [MST] in days).

Results

The dogs in the palliative care only group had an MST of 112 days, dogs that received an amputation only had an MST of 257 days, and dogs that had amputation followed by chemotherapy has an MST of 415 days. Based on the analysis the dogs in the palliative care only group had a significantly decreased MST as compared to both the amputation only group and the amputation and chemotherapy group, however the difference in MST between the amputation only group and the amputation with chemotherapy group was not statistically significant.

Significant independent variables were weight in the amputation only group (decreased the MST) and an increased histologic score in the palliative treatment group (also decreased MST). While breed was not statistically significant, the most commonly represented breed in the study was the miniature schnauzer.

In comparison to larger breed dogs studied, the small breed dogs who underwent amputation only as the treatment did have a longer MST. For dogs that received both amputation and chemotherapy as treatment there was not a significant difference in MST for small dogs in this study and dogs in the studies that included all sizes of dog (as compared to larger breed dogs previously studied).



The 7 Dog Breeds At The Greatest Risk For Bone Cancer



Pathologic fractures associated with osteosarcoma

Bhandal, J., Boston, S., *Pathologic fracture in dogs with suspected or confirmed osteosarcoma* Veterinary Surgery, 40, pp. 423-430, 2011.

Objective

An evaluation of the clinical presentation of pathologic fractures associated with confirmed or suspected osteosarcoma in dogs, and an assessment of the characteristics of these fractures, treatment, and survival times in these patients.

Methods

A retrospective study reviewing the cases of 25 dogs with pathologic appendicular fractures and either a confirmed or suspected diagnosis of osteosarcoma.

Radiographic details, histopathology, and cytology findings were recorded and reviewed; and the overall median survival time was calculated.

Results

21 of the dogs experienced a minor trauma to trigger the fracture at the suspected bone lesion site. In 4 dogs the trigger was unknown. 60% of the dogs included in the study were lame prior to the fracture.

5 of the fractures were closed, short oblique fractures, 5 were closed, spiral fractures, 2 were long oblique fractures and 2 were

collapsed moderately displaced fractures. There were also one each of the following fracture types. Most commonly the fractures were nondisplaced fractures with minimal comminution.

As osteosarcoma commonly metastasizes in the lungs, dogs received chest radiographs as well, but there were no lung lesions in any dog at the time of the fractures.

13 of the dogs were euthanized immediately after diagnosis, as elected by owners, and 4 were euthanized after a delay of more than 10 days. One dog received no further treatment and died of natural causes 90 days following diagnosis.

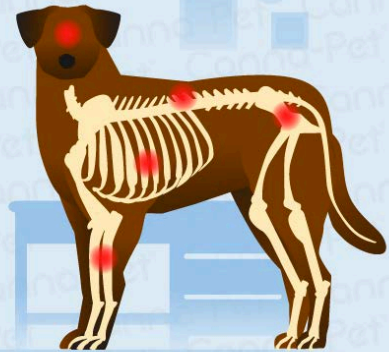3 dogs were treated with amputation alone, 1 with a combination of amputation and chemotherapy, and 3 treated the fracture with internal fixation. The median survival time of treated dogs was 406.5 days.

The dogs that were treated had a median survival time that was significantly longer than the expected survival time typically associated with dogs diagnosed with osteosarcoma. Given that the pulmonary radiographs for the dogs in this study were clear at time of fracture, that would suggest that the fractures occurred, and allowed for the osteosarcoma diagnosis, before the common metastasizing to the lungs that is often the cause of death in osteosarcoma. The authors consider that this means that treatment of the fracture (either

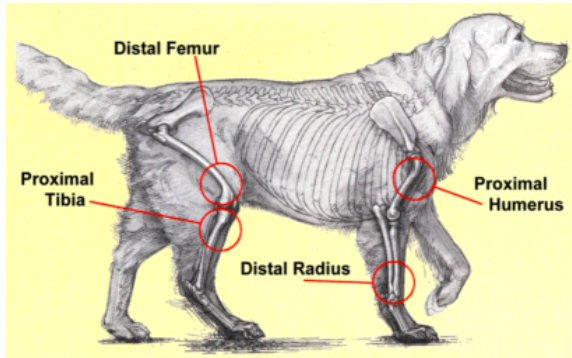
Where in the Body Does Osteosarcoma Usually Occur?

Osteosarcoma can affect all bones of the body

- ✓ The limbs account for 75-85% of all osteosarcoma cases
- ✓ The rest of cases are found in the axial skeleton (maxilla, mandible, spine, cranium, ribs, nasal cavity, paranasal sinuses and the pelvis)



through amputation or internal fixation) followed by a chemotherapy treatment should be considered to be feasible treatments for dogs diagnosed with osteosarcoma following a pathologic fracture.



Rubin, J.A., Suran, J.N., Cimino Brown, D., Agnello, K.A., *Factors associated with pathological fractures in dogs with appendicular primary bone neoplasia: 84 cases (2007-2013)* Journal of American Veterinary Medical Association, 247(8), pp. 917-923, 2015.

Objective

To determine the incidence of pathological fractures and identify possible risk factors for pathological fractures associated with primary appendicular long bone tumours in dogs.

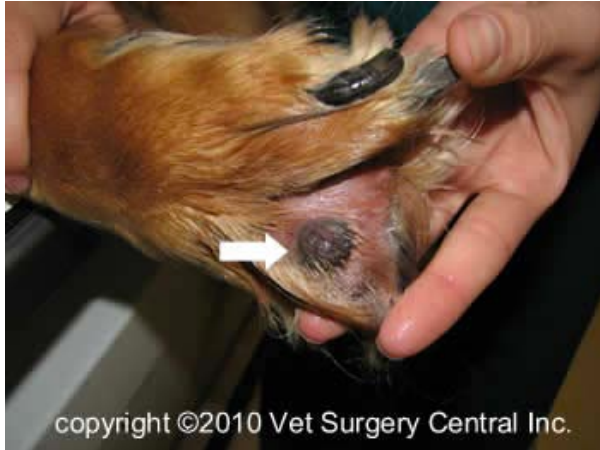Methods

This retrospective study analyzed the case files of 84 dogs that were treated for primary long bone neoplasia, diagnosed via radiography while the dog was living, and confirmed later by necropsy. 85 limbs were affected, and 78 of those were diagnosed as osteosarcoma as the most common tumour. Information was gathered from the diagnostic radiographs by a board-certified radiologist. Information about the affected bone, location of the fracture and tumour, cortical lysis, and the compression surface affected by lysis was analysed. Measurements of maximal axial cortical involvement, length and width of the most severely affected cortex, and width of the lesion were measured with software.

Results

Many of the variables measured showed no statistically significant association with pathological fracture. However, data did show that radial primary bone tumours were less likely to fracture, possibly due to a splinting role played by the ulna; and lytic tumours were more likely to fracture, a similar result is found in human studies.

Digital Squamous Cell Carcinomas & the Melanoma Vaccine



Belluco, S., Brisebard, E., Watrelot, D., Pillet, E., Marchal, T., *Digital squamous cell carcinomas in dogs: Epidemiological, histological, and immunohistochemical study* Veterinary Pathology, 50(6), pp. 1078-1082, 2013.

Malignant neoplastic processes account for 53.5% of all digital lesions in dogs, and squamous cell carcinoma (SCC) is the most commonly diagnosed tumour. Affected animals have a mean age range between 7 and 9.8 years, depending on the study. No sex predisposition has been described, and some breeds have been reported as overrepresented, particularly Rottweiler, Giant Schnauzer, Standard Poodle, and Dachshund. Multiple digits can be affected, and metastases have been recorded, with a prevalence ranging from 5% to 25% to local lymph nodes and lungs. 47.4% of malignant canine digital lesions are squamous cell carcinoma.

Objective

The aim of this study was to provide a better characterization of canine digital squamous cell carcinoma (CDSCC), the clinical outcome, and clinically relevant prognostic factors.

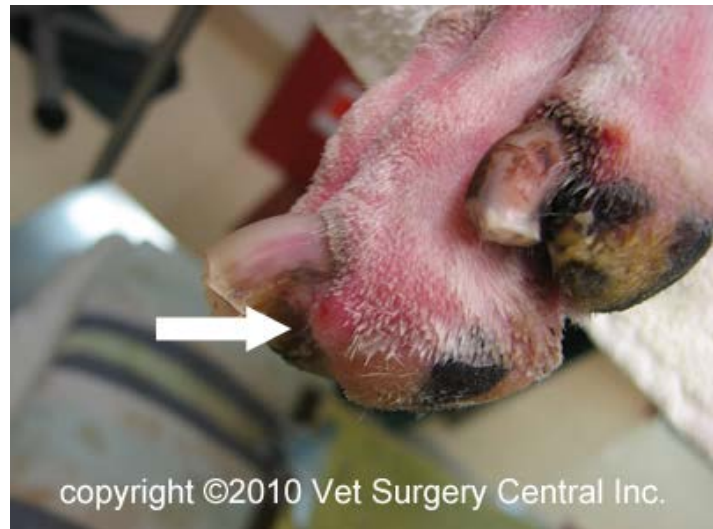Methods & Results

154 cases, with 49 follow-ups, were studied. The average age of affected dogs was 10.2 years, and the most common breeds were Rottweiler, Schnauzer, Beauceron, Briard, and Miniature Poodle. Results demonstrated that dark haired animals accounted for 94% of the cases, and large/giant breeds were 75.2% of the cases. The forelimb was twice as affected as the hindlimb, with no difference between right vs left limbs or among different digits.

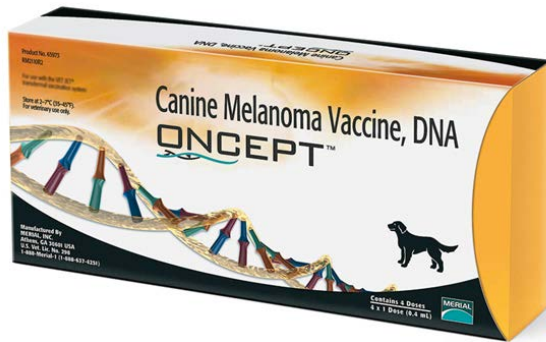
At the time when follow-up questionnaires were sent to all submitting veterinarians, 30 dogs were dead, 18 were alive, and 1 was lost at follow up. Twenty percent of the deceased animals were as the result of a direct relation to CDSCC. Four dogs had probable metastases and new tumour development on other digits was recorded in 22.4% of the follow-up cases.

The observed tumours were located in the superficial, mid, and deep dermis, often invading the adjacent bone. They were multilobular, not encapsulated, and moderately cellular. The stroma was moderate in amount and infiltrated by lymphocytes and plasma cells. Tumours often showed more than one differentiation type. Neoplastic emboli with several different morphologies could be observed in a few cases.

Owners often choose euthanasia when confronted with multiple tumours or future metastases. Little data is available for multicentric tumours and the only factor reported to predict metastatic disease is a histological grade, which seems to be unreliable. A breed predilection for large, black coated breeds has been reported. 94 % of dogs in this study had a dark (black, grey, or black/tan) coat. The nail colour



could have a role in development of SCC of subungual origin, but this was not known in this study. It has been reported that survival rate of non-subungual digit SCC was less than that of subungual SCC. Our data suggest that CDSCC has a scant risk of emboli and a lower risk of metastasis. Multicentric tumour development seems to be more frequent than metastasis-related death, according to this study, and no epidemiological factors were linked to an increased predisposition to develop multiple tumours. In some cases we found a mesenchymal phenotype, which was linked to the differentiation degree of tumoral cells. Future research into genetics and tumoral microenvironment can improve understanding of carcinogenesis in these cases.



McLean, J. L., Lobetti, R. G., *Use of the melanoma vaccine in 38 dogs: The South African experience* Journal of the South African Veterinary Association, 86(1), Art. #1246, 2015.

Melanoma is a spontaneously occurring, highly aggressive and frequently metastatic neoplasm

that affects the oral cavity, nail bed, footpad, mucocutaneous junctions, and skin as described in Bergman et al, 2006. It is the second most common tumour affecting the digit in the dog. Dogs with advanced disease have a survival time of 1 to 5 months with aggressive local excision. Other treatment approaches have an extended median survival time (MST) up to a year, with a study on intralesional cisplatin treatment for malignant melanoma reporting a partial to complete response in 70% of the cases.

The concept of vaccinations against tumours goes back to 1893, where it was observed that sarcomas regressed in humans with acute bacterial infections, leading to the hypothesis that the infection stimulated the immune system, which responded to destroy the tumour. Oncept, a xenogeneic DNA vaccine using human tyrosinase, was developed for use in dogs. It is registered for use in management of dogs with stage II or III oral melanoma after local control has been achieved. It is administered intramuscularly with a transdermal device.

Initial studies revealed a partial to complete response, with a median survival time of 389 days. Further studies showed that dogs with oral melanoma survived significantly more than historical controls; however, a more recent study did not provide any evidence that vaccination affected the outcome greater than historical controls.

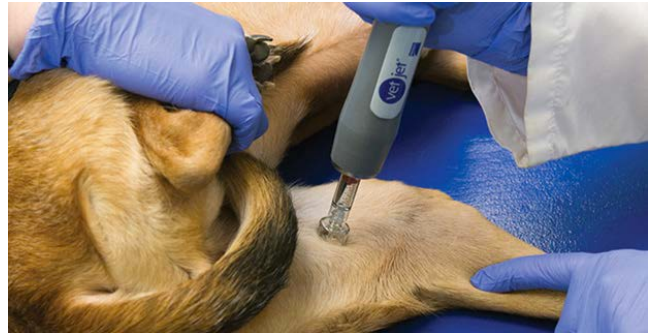Objective

The purpose of this study is to document the experiences with the Oncept vaccine.

Method

Inclusion criteria for the study include a histopathological diagnosis of melanoma, surgical excision of the tumour, and a complete initial induction vaccination course with Oncept. 38

dogs were selected; 25 had oral, 6 had digit, and 7 had infiltrative cutaneous melanoma in other sites. The six digital stage II cases with an equal sex distribution and a mean age of 8.5 years lived to the end of the study, except for one, due to surgery for resection of a rib osteosarcoma. At the end of this



study, 83% were still alive with a MST of 36 months with no deaths due to a progression of the disease. This survival time is longer than that reported in historical controls treated with surgery. Dogs in this group were primarily large breed. Unlike in previous studies, the hind limbs were more frequently affected than the forelimbs.

Results

Of the 38 dogs in this study, MST of dogs that were still alive was 29 months versus 8 months for those that died of progressive disease. There were no adverse effects due to the vaccine. This study showed that a combination of surgical excision and vaccination with Oncept can increase survival times in dogs with malignant melanoma of the oral cavity, digit and other sites.

Treatment and outcomes, limb sparing and amputation

Szewczyk, M., Lechowski, R., Zabielska, K., *What do we know about canine osteosarcoma treatment? - review Veterinary Research Communications, 31, pp. 61-67, 2015.*

Objective

A literature review that discusses Osteosarcoma (OSA), the most common type of bone tumour in dogs that accounts for 80% of malignant bone tumours in dogs, its etiology, pathogenesis, risk factors, therapies (drug and otherwise) that prolong the life of dogs diagnosed, and those that have been proven ineffective and the reasons for their failure. The advantages and disadvantages of limb amputation vs limb sparing surgery are also discussed.

Discussion

Osteosarcoma most commonly affects large and giant breed dogs (with a body weight greater than 40 kg) between the ages of 6 and 10 years. Males are more commonly diagnosed than females, and dogs that were spayed or neutered under the age of 1 year are significantly more likely to develop OSA than intact dogs. 64% of tumours occur in the appendicular skeleton (more often in the forelimbs than in the hind limbs), 28.5% in the axial skeleton (ribs and skull), and 7.5% in the extraskkeletal muscles.

Tumours localized at the distal radius are less likely to metastasize than those at the distal femur, proximal tibia, or proximal humerus, which are associated with a significantly higher mortality.

Physical examination is usually performed following the appearance of the most common clinical sign, lameness and local swelling at the tumour site. Radiography and fine needle biopsy are used to identify the tumours. There is a high risk of metastasis to the lungs, so a chest X-ray is often performed where OSA is suspect.



Amputation and Limb Sparing Surgery

Amputation of the affected limb in cases of OSA in the appendicular skeleton can increase the survival rate while providing pain relief and is a treatment thought to delay euthanasia by removing the primary tumour in its entirety.

A limb sparing surgery involves the removal of the tumour by removing the section of bone that is affected and replacing it with an implant. This procedure results in a restoration or preservation of use of the affected limb in over 80% of cases, but is associated with a rate of infection of 30-50% and rate of implant failure of 20-40%. In 15-20% of these cases, the tumour recurs.

Regardless of which surgical route is chosen surgery alone does not show a long median survival time (138 days). Micrometastases occur in over 90% of dogs, and 72.5% of dogs treated with amputation alone die or are euthanized shortly afterwards.

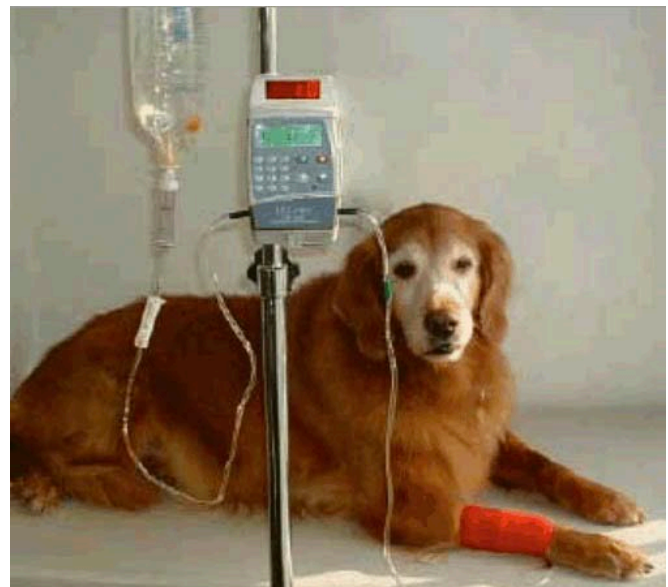Chemotherapy

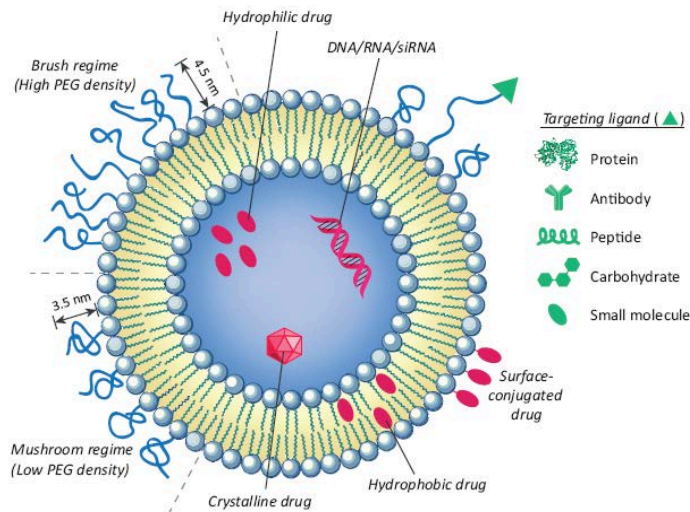
The most commonly used cytostatic drugs are Carboplatin, Cisplatin, and Doxorubicin.

Carboplatin administration following amputation increases the median survival time to 307 days, which is similar to Doxorubicin (366 days) and Cisplatin (322 days). However, while these drugs may prolong life, none of these drugs effectively inhibit metastasis, which is the reason for euthanasia in most cases.

Other alternative chemotherapy drugs are lobaplatin and ifosfamide. Lobaplatin prolongs the disease free interval for dogs treated with surgery, and increases survival time. 20% of dogs treated with Lobaplatin achieved one year disease free, and 30% reached 365 days survival time. Ifosfamide, however, shows only minor anti-tumour activity.

Investigation into whether survival times are improved with the combination of multiple chemotherapy drugs, given on an alternating schedule showed that while the drugs appear to be better tolerated by patients, therefore possibly increasing the quality of life, the median survival time was not significantly improved. Additionally, no additives to the chemotherapy drugs have shown significant improvement in median survival times.





Overcoming multidrug resistance

Multidrug resistance (MDR) is a significant cause of the ineffectiveness of chemotherapy treatment. The MDR1 gene is responsible, causing an increase in the activity of efflux pumps which prevents the intracellular accumulation of the drugs in the

cancer cells. This can be overcome by encapsulation of the drugs in liposome-based dextran nanoparticles to bypass the pumps.

Radiotherapy

Radiation therapy is considered a palliative treatment for dogs with OSA, decreasing pain and prolonging life. It requires general anesthesia. The longest survival times are achieved with the combination of radiotherapy and chemotherapy, vs radiotherapy alone.

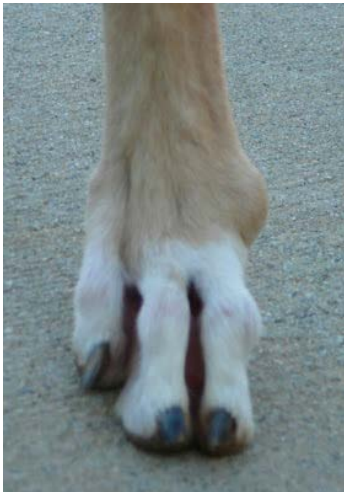Conclusions

Overall, the most effective course of treatment for OSA in dogs to increase the median survival time, is a combination of surgery (either amputation or limb sparing), chemotherapy, and radiotherapy. The authors propose that a promising next step would be further investigation on the possibility of using nanoparticles to increase the efficacy of chemotherapy drugs.

Szewczyk, M., Lechowski, R., Zabielska, K., *Diagnosis and clinical outcomes associated with surgically amputated canine digits submitted to multiple veterinary diagnostic laboratories* Veterinary Pathology, vol. 44, pp. 355-361, 2007.

Objective

The purpose of this study was to define prevalence of neoplasia and prognoses for neoplastic diseases by examining the diagnoses in digits submitted to veterinary diagnostic laboratories. Biopsies that included some portion of bone from a 6 year period and a 7 year period were considered in this study. Second, sometime third, diagnoses were compared with the original diagnosis and only the cases with majority diagnosis were included. A survey was sent to all original veterinarians to collect follow-up information for each case; including treatment, date of recurrence, metastasis, survival, and cause of death or last date of examination. The risk factors under consideration were sex and neuter status, age, breed, leg of origin, and digit of origin.



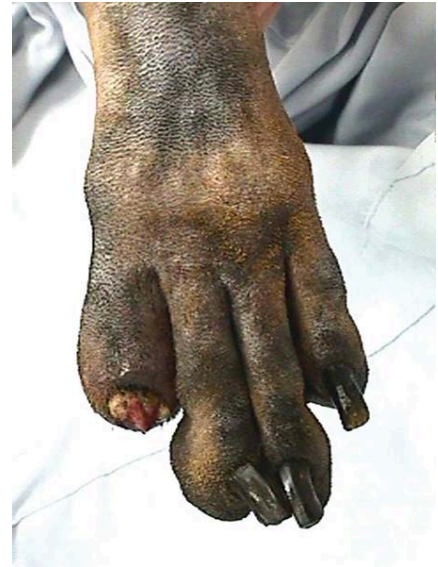Method

Amputated digits from 428 dogs were included in this study, with 67 breeds of dogs represented. The most common were mixed, Labrador Retriever, Golden Retriever, Cocker Spaniel, Rottweiler, Giant Schnauzer, Standard Poodle, German Shepherd Dog, Doberman Pinscher, and Scottish Terrier. Multiple digits were affected in 34 dogs. 30 different diagnoses were identified; with 53.5% being malignant neoplastic processes, benign neoplastic or noninflammatory non-neoplastic processes in 15.7%, and inflammation in 25.5% of the cases. 172 of 202 female dogs were spayed. 132 of 184 male dogs were neutered. 255 submissions identified the affected leg. Those where only front or only hind limbs were affected, the front leg was more often affected (62%) as compared to the hind (37.2%). Lesions were less likely to occur on a dewclaw (9.9%) than any other digits. The response rate of the survey was 46.7%.

Results

Inflammatory conditions that were primarily pyogranulomatous were the only abnormalities in 108 submissions. The mean age of time of amputation was 7.1 years and the age range was 1 to 14 years. 50 were females and 50 were males, no sex was identified for 8 cases. The mean age of animals with inflammatory conditions was younger than that for animals with squamous cell carcinoma, melanoma, soft-tissue sarcoma, mast cell tumours, and benign neoplasms.

SCC was the most common diagnosis and most common malignant neoplasm. Mean age at time of amputation was 9.8 years. 50 female and 59 male dogs were affected. Multiple digits were affected in 7 of the submissions. The diagnosis of SCC was overrepresented in several breeds of dogs; including Rottweilers, Giant Schnauzers, standard Poodles, Dachshunds, and Flat Coated Retrievers. 42 surveys were returned for dogs with SCC. 10 of these dogs developed metastatic disease with a mean time of 309 days. Of the 11 dogs that died due to the disease, most died within the first year after amputation and diagnosis. This compromises of less than 50% of deaths related to disease, so no median survival time can be determined.



Melanoma was the second most common malignant neoplasm. Mean age at time of amputation was 9.9 years. Females were more commonly affected than males. Multiple digits were involved in two submissions. Scottish Terriers were overrepresented. Surveys were returned on 22 dogs. 11 had metastasis with a median disease-free interval of 322.1 days. All of them died due to metastatic disease, the median survival time was 365 days.

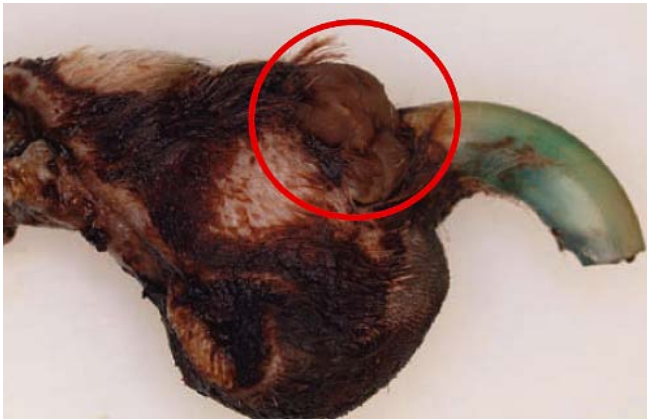Soft-tissue sarcomas compromised of 7.4% of the malignant neoplasm cases. Mean age at time of amputation was 9.3 years. Sex in 22 submissions was identified; 11 were female and 11 were male dogs. Surveys were returned on 17 dogs. Two dogs developed metastatic disease, one at 274 days and the other at 577 days. One was euthanized at time of diagnosis (577 days) and the other one was euthanized at 608 days.

Mast cell tumours were diagnosed in 20 dogs, with a mean age of 9.2 years at time of amputation. 13 females and 7 males were diagnosed. A dog had multiple digits on the same foot involved at time of amputation. Surveys were returned on 8 dogs. 3 dogs developed metastatic disease and died subsequently, resulting in a 1 year survival rate of 75% and 2 year survival rate of 62.5%.

Osteosarcoma was diagnosed in 7 dogs, with a mean age of 11.1 years at time of amputation. Four females and 3 males were diagnosed, with 6 being large breed and 1 was

a Dachshund. Of the four surveys returned, two had metastatic spread and were euthanized at time of diagnosis.

Various benign neoplastic and noninflammatory, non-neoplastic disease were diagnosed. The average age at time of amputation was 9.4 years. The most common benign changes were epithelial inclusion cysts and keratoacanthomas.



Neoplastic changes were present in 294 digits out of 404 submissions, with only 108 having inflammatory changes. 33 different neoplastic diagnoses were identified, with malignant neoplastic changes more commonly seen than benign changes. Multiple digits on the same dog were involved in malignant, benign, and inflammatory conditions. The age range on

all conditions was broad and overlapped considerably. This study found that most neoplasms in the digit occur on the front limbs. Possible reasons for this predilection and apparent sparing of the dew claw digit may be due to dew claw removal in puppies, the front limbs bear more weight than hind limbs, and possible exposure to carcinogens during digging activities.

In agreement with most other studies, SCC was the most common diagnosis and most common malignant diagnosis. A breed predisposition for large breed, black coated dogs has been reported, and was seen in this study. The reason for the relationship of hair coat colour to the incidence of SCC in the digit is unclear, but masses in multiple digits in a black-coated breed should raise suspicion of SCC. Evidence in this study suggests that SCC of the digit is more likely to metastasize than SCC occurring elsewhere in the body.

The results of this study show that benign and malignant neoplastic disease were the largest proportions of abnormalities in surgically amputated canine digits submitted to several veterinary diagnostic laboratories. Malignant neoplasms were 229 of the 296 neoplasms diagnosed. Diagnosis of the disease without histopathologic evaluation is unlikely as simultaneously affected digits and bone lysis were present in both malignant and benign neoplasms and non-neoplastic noninflammatory disease as well as inflammatory conditions.




FourLegRehabInc

CANINE REHAB EDUCATIONAL RESOURCES

See what else is available to learn:

Visit www.fourleg.com

Drop me a line! Send me your questions!



Four Leg Rehab Inc

PO Box 1581,
Cochrane, AB T4C 1B5
Canada

Laurie@Fourleg.com